

# OLYMPIC CFM 6000

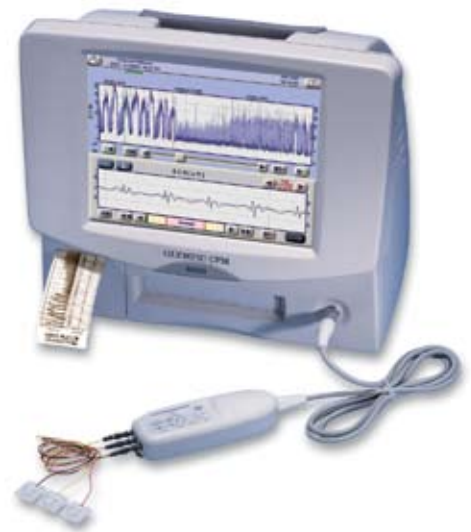## A Clinical Guide

### Overview of the Olympic CFM 6000

The Olympic CFM 6000 aEEG Infant Monitor records aEEG signals from a pair of electrodes placed on the infant's head. The signal is filtered, rectified and compressed, according to the original Prior and Maynard CFM algorithm. The signal is displayed in microvolts ( $\mu\text{V}$ ) at a rate of 1 mm per minute (6 cm/hour). Each division on the CFM trace display is equal to 10 min of aEEG. The length of the display is 3 hours.

The CFM simultaneously displays the underlying EEG to aid in seizure and artifact identification.

The algorithm used in the CFM focuses on changes in amplitude in the EEG — it is referred to as aEEG — amplitude-integrated EEG.



### General interpretation

- Presence of Sleep/Wake cycle
- Amplitudes of the upper and lower margins of the trace — in micro-voltage ( $\mu\text{V}$ )
- Variability — narrow or broad trace.
- Brain Activity
  - Continuous (normal) — dark central band of continuous activity, with normal amplitudes
  - Discontinuous (abnormal) — a wide trace with no central band of activity; appears universally gray
- Presence of seizure activity

### Understanding aEEG

- Quiet/active cycling — also known as sleep/wake cycle — trace is narrow when infant is awake (or in active sleep) and widens during quiet sleep; typically cycles every 90 min, but is dependent on infant condition
- Continuous normal voltage (CNV) — a narrow band on the aEEG with dark central band indicating a continuous normal high level of activity with little variability
- Discontinuous normal voltage (DNV) — a wide band on the aEEG that appears universally gray, indicating increased variability in activity primarily due to intermittent lower levels of activity
- Burst suppression (BS) — a comb pattern in the aEEG due to the longer low voltage (suppressed) period than with a discontinuous EEG and occasional bursts of activity (high amplitude)
- Flat EEG — a relatively flat trace at the bottom of the aEEG scale
- Seizure — depending on the seizure morphology, this can resemble an 'upward notch' (rising and narrowing) in the aEEG. Status epilepticus = continuous seizures  $\geq 30$  min.

### Applying electrodes

#### **Placement**

- Biparietal is the optimal location — P3/P4 — this is the watershed area between the posterior and middle cerebral arteries. This area is least likely to be affected by scalp muscle activity and eye-movement artifacts. Low-impedance needle electrodes are recommended in the scalp application.

#### **Hydrogel electrodes — can be used on scalp (biparietal) or forehead**

- Requires aggressive preparation for cleaning to assure adequate adherence. These electrodes should be replaced every 24 hours.
- Assure impedance is  $< 20 \text{ k}\Omega$  (ideally closer to  $0 \text{ k}\Omega$ )

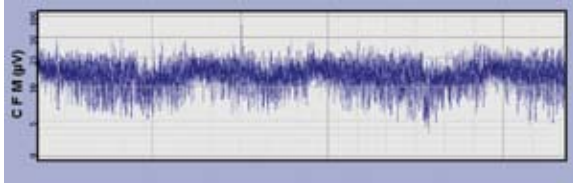
#### **Low-impedance needle electrodes**

- Insert sub-dermally in parietal position (P3/P4); secure with tape and create strain relief to avoid inadvertently dislodging the electrodes. These electrodes can be left in place for days, if needed.

## CFM 6000 Trace Examples

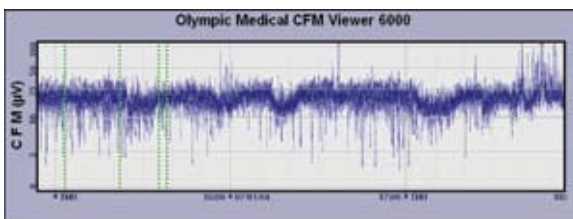
### Normal Trace (Continuous with Cycling)

- Evidence of Sleep/Wake Cycling
- Upper margin > 10  $\mu$ Volts & Lower margin > 5  $\mu$ Volts
- Limited Variability (narrow band)



*Notice the dark central band of continuous activity.*

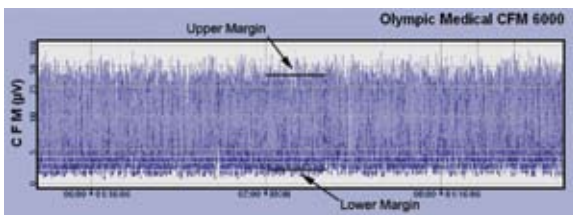
### Continuous, No cycling



*Notice what appears to be Sleep/Wake cycling, however, it occurs more frequently than normal. This is indicative of some underlying condition, or suspicion of artifact.*

### CFM — Moderately Abnormal trace (Discontinuous pattern)

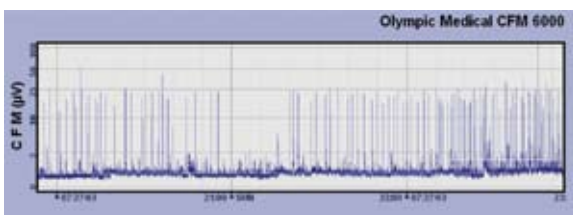
- No evidence of Sleep/Wake cycling
- Upper margin > 10  $\mu$ Volts & Lower margin < 5  $\mu$ Volts
- Increased variability (trace is broad)



*This discontinuous pattern can be seen in infants with moderate/severe encephalopathy or in healthy infants immediately after administration of drugs, like anticonvulsants and sedatives. No dark central band is seen. Notice the universal gray color.*

### CFM — Severely Abnormal (Inactive, flat trace)

- No evidence of Sleep/Wake cycling
- Upper Margin < 10  $\mu$ Volts
- Greatly reduced variability



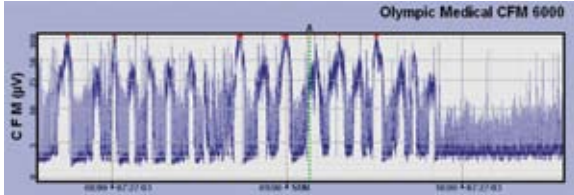
*General suppression of amplitude — trace is narrow, with low voltage.*

*May be accompanied with brief bursts of higher voltage (burst suppression).*

*Can be accompanied by seizure activity. More severe insults will be narrow and voltage reduced (< 10 $\mu$ V)*

## CFM Seizures

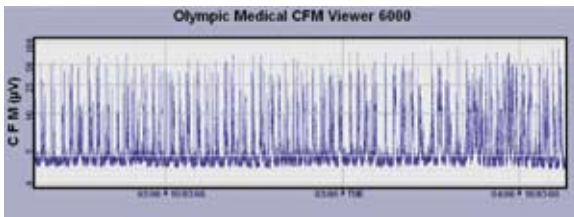
- Seizure onset shows continuous high activity
- Causes CFM to narrow and rise up



Seizures show a decrease in variability as the level of electrocortical activity rises, represented by a sudden narrowing and rise in the band of activity. The lower margin rises and often the upper margin rises as well. With Insight, note the dark band at the upper edge of the upper margin.

Infants with a normal interictal band of activity can have a mild hypoxic-ischemic insult or the seizure may be due to a cerebral infarction or a biochemical abnormality such as hypocalcemia.


## Status Epilepticus (Continuous Seizures ≥ 30 minutes)




Notice the sawtooth pattern seen in Status Epilepticus. It is produced as the brain rapidly moves in and out of seizure.

## Impedance

Measures quality of electrode contact and should be as low as possible. It is also used to detect lead motion artifact. The CFM 6000 monitor will Alarm if  $> 20\text{k}\Omega$ .

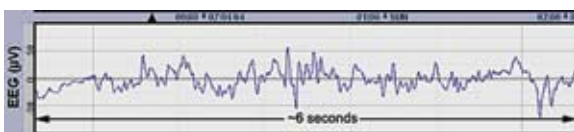


Normal impedance at 0 kΩ



Abnormal impedance ( $>20\text{k}\Omega$ ). Alarm sounded because leads were removed/disconnected from patient.

## EEG Display



It is important to inspect the underlying EEG to confirm the presence of seizures and to distinguish artifacts from real signal.

## Prediction of HIE Outcome

Clinical signs — continued need for resuscitation @ 10 minutes after birth, 10-min Apgar score <5, acidosis - cord pH <7 within 60 minutes of birth, Base Deficit  $\geq$  16 mmol/L within 60 min of birth

Neurological signs — altered state of consciousness (lethargy, stupor, or coma), hypotonia, abnormal reflexes (including oculomotor or papillary), absent or weak suck, clinical seizures

## Scoring of HIE

Amplitude	Score	Description ( $\mu$ V)	Interpretation/Prediction
Normal	1	Upper margin > 10 Lower margin > 5	1 = Normal long-term outcome
Moderately Abnormal	2	Upper margin > 10 Lower margin < 5	2, 2S = Moderate HIE
Severely Abnormal	3	Upper margin < 10	3, 3S = Severe HIE with poor long-term prognosis
Seizures	S		1S = indicative of a focal lesion rather than a global HIE insult

## CFM 6000 monitoring

### Pitfalls to watch for

- Background voltage appears elevated — Possible causes:
  - ECG artifact
  - Handling
  - Muscle activity
  - High-frequency ventilation
  - Status epilepticus
  - Gasp artifact
- Background voltage appears depressed — Possible causes:
  - Severe scalp edema
  - Leads significantly too close together
  - Significant sedation

### Tips for avoiding pitfalls

- Carefully place electrodes — always check the impedance
- Properly place and label markers for any care/procedures, concerning movements and specific medications
- Look at the raw EEG display to evaluate for artifact and help identify seizures



Natus Medical Incorporated  
5900 First Avenue South • Seattle, WA 98108 USA  
Sales & Support: 1-800-303-0306 • +1-650-802-0400 (worldwide)  
www.natus.com

©2009 Natus Medical Incorporated

DOC-000114A